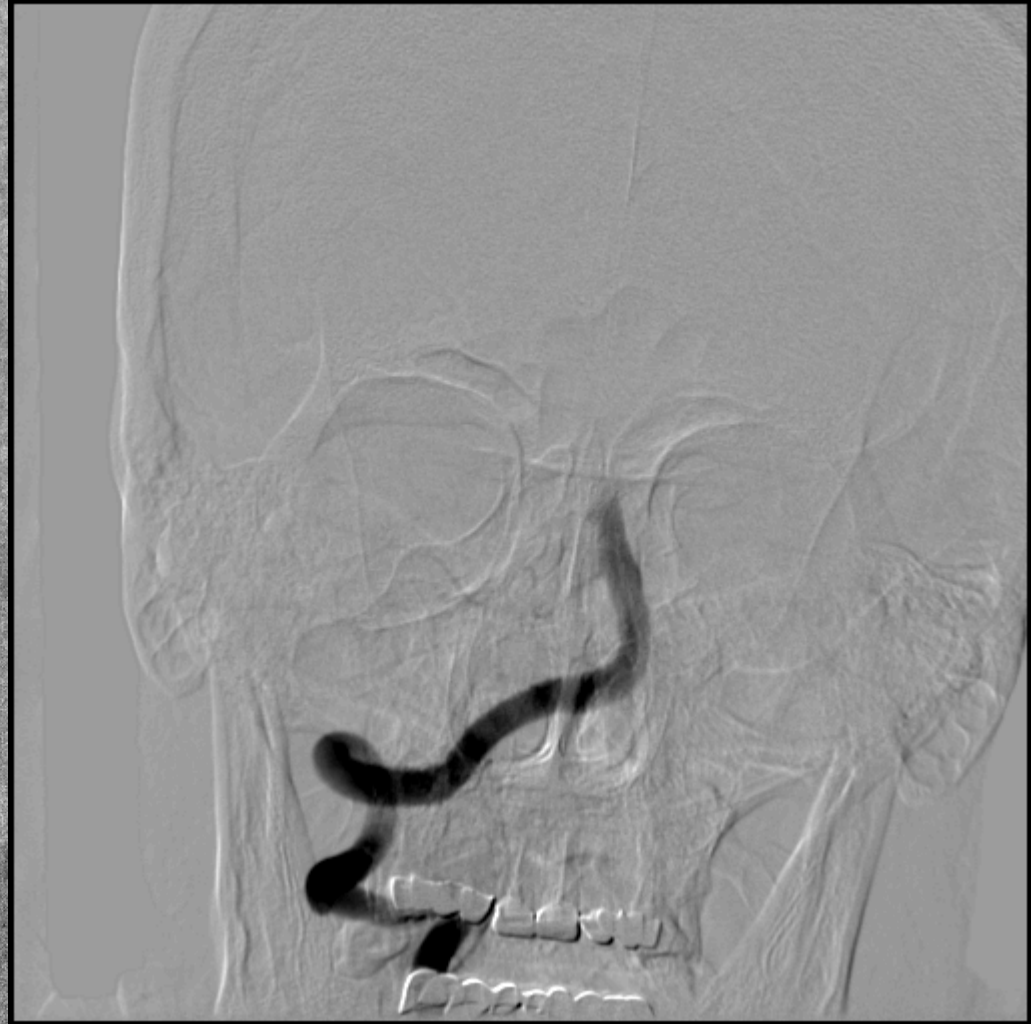
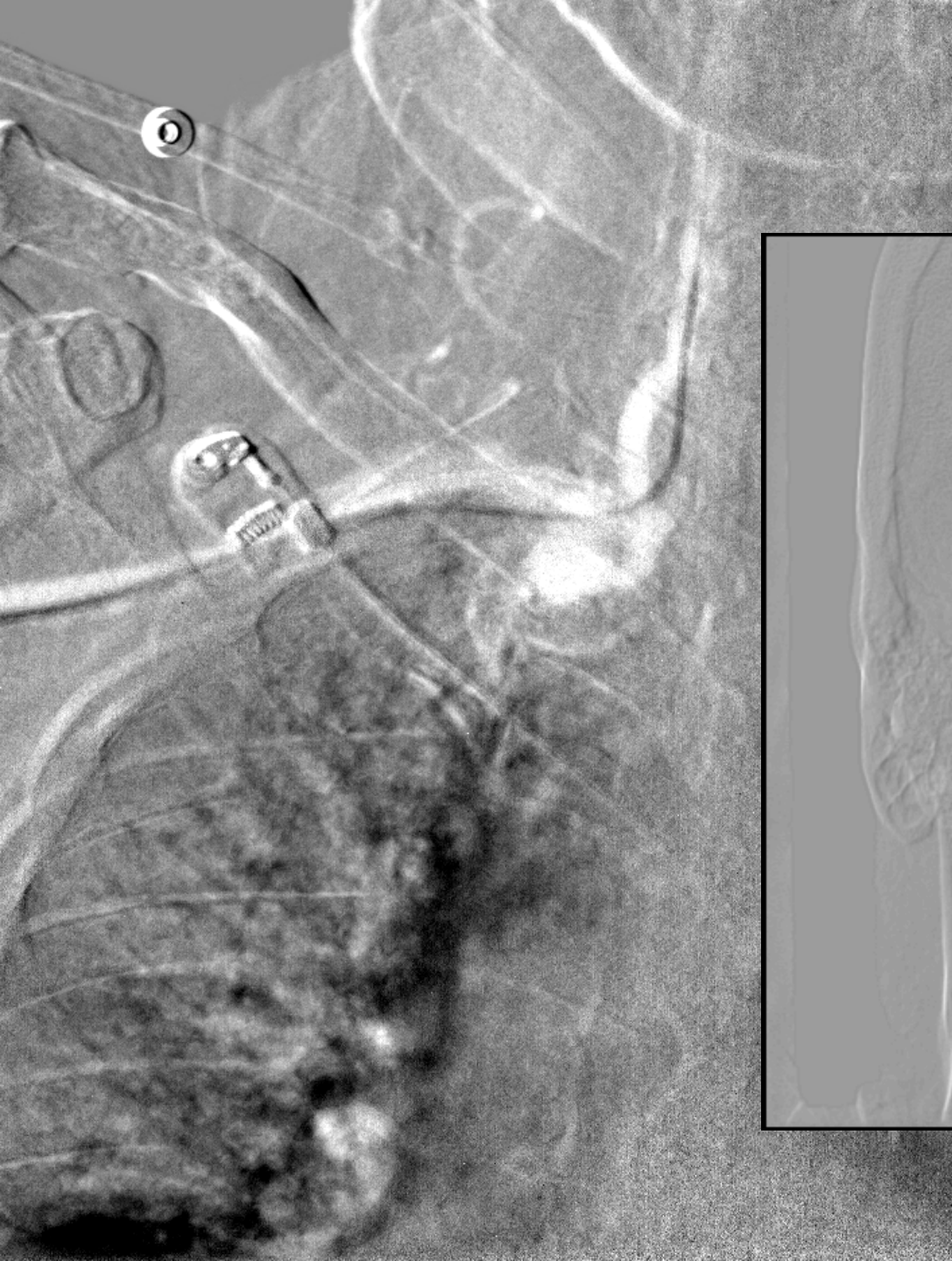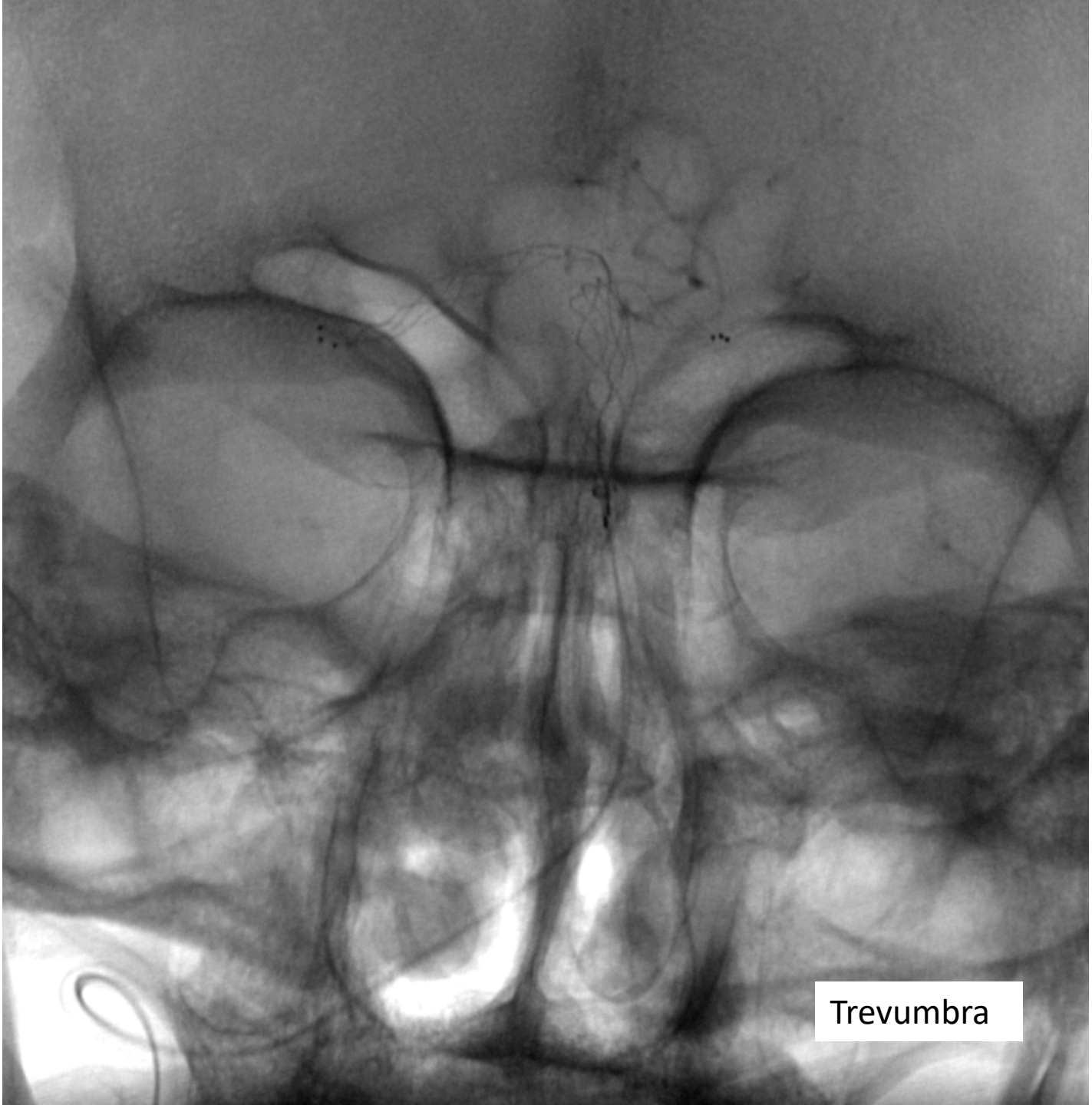


Caso 3

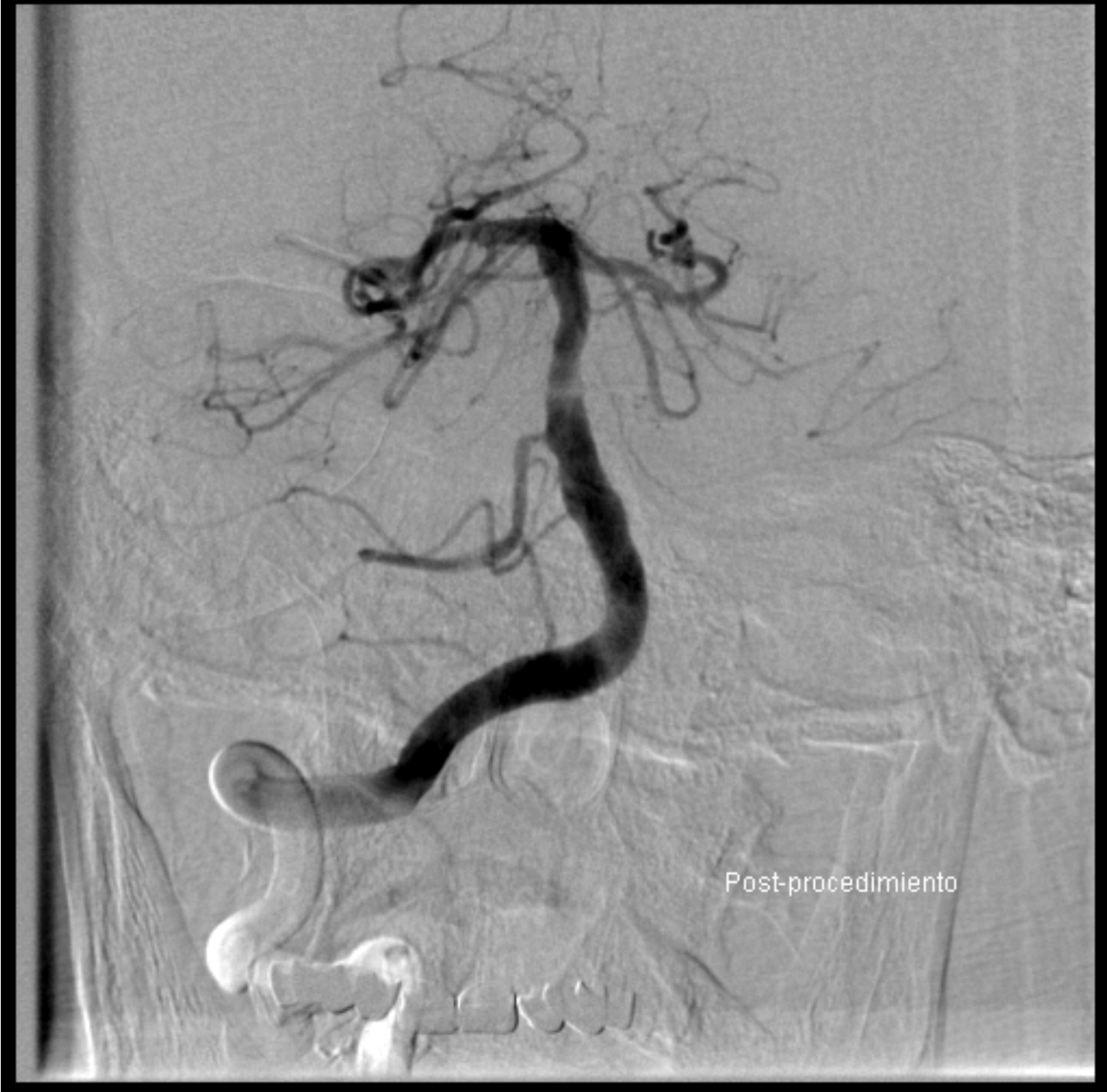Oclusión basilar

Acceso radial derecho





Trevumbra



Post-procedimiento